

# Caldwell Luc Approach in Extirpation of Dentigerous Maxillary Cyst on 13 Year Old Boy with Odontogenic Sinusitis: A Case Report

Teuku Husni T.R., Rahmawati Ega Suharno

Department of Otorhinolaryngology, Head and Neck Surgery, Faculty of Medicine, Universitas Syiah Kuala, Zainoel Abidin General Hospital, Banda Aceh, Indonesia

---

**Keyword:**

Dentigerous maxillary cyst,  
ectopic teeth,  
odontogenic sinusitis,  
Caldwell Luc

**Abstract**

**Background:** Dentigerous cyst is an oral fluid formed between the crown tooth formed and the enamel epithelium which is reduced, and is associated with impaction or developing teeth, appearing slowly and benignly. Dentigerous cyst can occur in odontogenic sinusitis if there is a secondary infection.

**Purpose:** Presentation of this case is to show Caldwell Luc procedure extirpation of dentigerous maxillary cyst with odontogenic sinusitis on 13 year old boy.

**Case Report:** One case of dentigerous cyst with an ectopic right maxillary canine tooth in a 13 year old boy who presented with sinusitis.

**Methods:** Using PubMed, Wiley Online Library, Semantic Scholar, Dental Sciences, ResearchGate and Hand searching to search for the evidence.

**Result:** Three valid prognostic articles were appraised for the validity, importance, and applicability in my clinical scenario.

**Conclusion:** In this evidence-based case report, selection of the type of surgery for dentigerous maxillary cyst can be extirpated by Caldwell Luc procedure combined with impacted tooth extraction. It was found that Caldwell Luc procedure combined with impacted tooth extraction had high success rate and prevent recurrences of dentigerous maxillary cyst.

---

**Corresponding Author:** [teukuhusnitr@unsyiah.ac.id](mailto:teukuhusnitr@unsyiah.ac.id) (Teuku Husni T.R.)

---

## INTRODUCTION

The terminology dentigerous cyst was created by Paget in 1953.<sup>1</sup> Dentigerous cyst is an oral lesion that usually formed from fluid accumulation between fully formed crown of the teeth and reduced enamel epithelium, impaction or developing teeth.<sup>2,3</sup> Dentigerous cyst is the most common cyst found in odontogenic cyst and it is reported with frequency of 18.1% and is the second most common type of jaw cyst.<sup>3,4</sup> Dentigerous cyst is most common in the second and third decades and is most common in men, accounting for about 25% of all odontogenic cysts of the jaw.<sup>2,5</sup> Dentigerous cyst is associated with impacted teeth, supernumerary and ectopic eruptions that don't grow.<sup>6</sup> Cyst arises from the separation of follicles from crowns of teeth that do not erupt.<sup>2</sup>

Ectopic eruption of maxillary sinus is a rare case. Buyyukurt et al conducted a study since 1980-2009 and reported 20 cases of dentigerous maxillary cysts with ectopic teeth.<sup>7</sup> At ENT Polyclinic, dr. Zainoel Abidin Banda Aceh in 2018-2019 found 4 cases of dentigerous maxillary cysts with male to female ratio of 1,5:1 and occurred in children.

The denture cyst usually appears slowly and it is benign. Initially asymptomatic, except for large cyst or secondary infection and involves the maxillary sinus, the patient will complain of facial swelling, facial pain, headache and nasal congestion.<sup>3,8</sup> When the cyst involves the orbital wall, symptoms of diplopia and even blindness will appear. Dentigerous cyst is generally solitary, benign odontogenic cysts, usually associated with late-growing teeth.<sup>5</sup>

Panoramic radiograph is a common diagnostic tool for dentigerous cyst. The image expansion of dentigerous maxillary cyst can be assessed from CT scan to determine the most appropriate procedure as treatment.<sup>7</sup> Enucleation, marsupialization and extraction of related teeth are the management of dentigerous cyst. The Caldwell Luc procedure is a successful treatment for dentigerous maxillary cyst.<sup>8,9</sup> The treatment of choice for dentigerous maxillary cyst is the enucleation and extraction of tooth associated with the Caldwell Luc approach.<sup>7</sup>

The purpose of filing this case report is to show

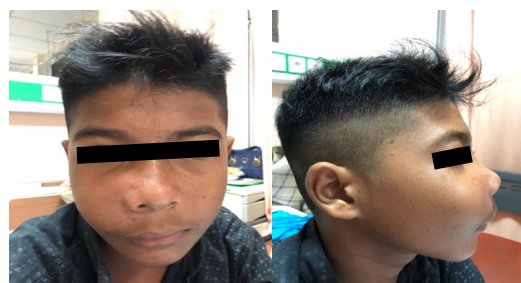Caldwell Luc procedure extirpation of dentigerous maxillary cyst with odontogenic sinusitis on a boy with tooth extraction that gives satisfactory results.

## CASE REPORT

A 13 year old boy, complained of right cheek lump for 5 months that grew to urge to the right nose, without pain, blocked right nose, yellowish right nasal discharge, and sometimes headache on the right side. The lump grows slowly, there is no history of nose bleeding, trauma, facial weakness, numbness and lump in the neck. History of taking antibiotic for amoxicillin-clavulanate for 2 weeks and complains did not reduce. Asymmetrical facial appearance caused by a lump from the right maxilla area. The size of the mass is 5x4x3 cm with firm boundaries, the color matches the surrounding skin, the consistency is chewy, not warm on palpation, and is fixed (picture 1). Anterior rhinoscopy showed that the right nasal cavity was narrow with yellowish secretion, bleeding was not found. Intra-oral examination showed no caries dentis and Post Nasal Drip (PND) existed.

Nasoendoscopic examination revealed the right lateral nasal wall was slightly pushed medially obstructing the nasal cavity and limiting the examination of posterior sinus and nasal anatomy on that side. Purulent right nasal discharge were noted coming out from middle meatus, while inferior and middle turbinate was within normal limits.

Panoramic radiograph shows a firm boundary zone with a base on the root and visible dental components in it and appears to urge the teeth in the



**Picture 1. Extra-oral appearance describes an asymmetrical face on the right side**

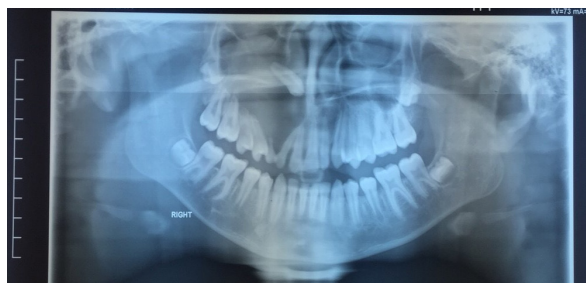
right maxilla and conclude the presence of dentigerous cyst, DD/radicular cyst (picture 2). The result of chest x-ray and blood test are within normal limits. Water's imaging provides good visualization of sinuses, but it is useless to detect an ectopic molar in maxillary sinus, while CT imaging removes structural superimposition. CT imaging of the paranasal sinuses without contrast shows hypodense lesion, firm boundary size around 3.45x3.45x4.14 cm in right to middle maxillary os and right maxillary sinus with bowing and thinning of the maxillary os cortex, visible teeth structure in the lesion. There is no visible connection or thickening of the mucosa in the ethmoidal, frontal, and sphenoidal sinuses. CT imaging of the paranasal sinuses by contrast shows the impression of the right maxillary dentigerous cyst (picture 3).

The patient was diagnosed with right dentigerous maxillary cyst with odontogenic sinusitis.

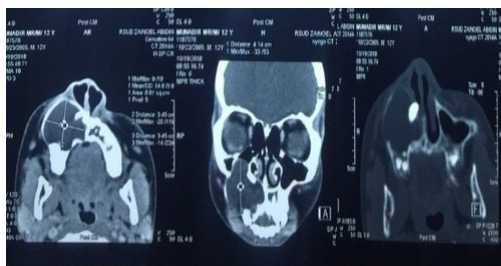
Extirpation of dentigerous maxillary cyst through Caldwell Luc procedure and tooth extraction in right maxillary sinus was performed under general anesthesia. Infiltration in the area of incision and an incision is made in gingivobuccal sulcus just above the teeth socket measuring  $\pm 2$  cm (from the canine

to the first premolar) through the mucosa and periosteum. The mucosa is sufficiently retained at the bottom to facilitate closure. Periosteum is elevated by rasparatory, the exposure is extended upwards to a point just below the edge of the orbita, where the infra-orbital nerve is identified and maintained. The front wall of the antrum can be opened using osteotom. Using Kerrison cunam, the hole is widened to a size suitable for exploration and purulent fluid is coming out from maxillary sinus (picture 4). The purulent fluid is suctioned and 00 telescope was passed through antrum's hole to explore the visible canine in maxilla wall, it's extracted by forcep and maxillary cyst extirpation is done (picture 5). Evaluation of bleeding by suction, absorbable gelatin sponge is placed in maxillary sinus, and suturing the incision wound.

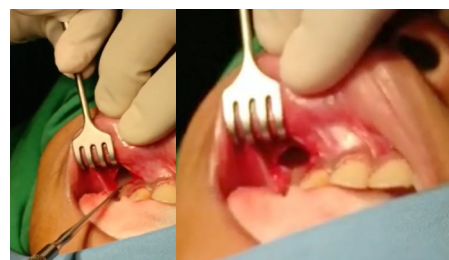
The patient was hospitalized and there is no diplopia, hypesthesia or right cheek paresthesia, infection, and bleeding, thus outpatient is allowed and the patient is advised to take oral clindamycin 150 mg q.i.d for 5 days. Seven days after the surgery, patient's face is symmetrical, there is no cheek hypoesthesia, lump on the right cheek, rhinorrhea,



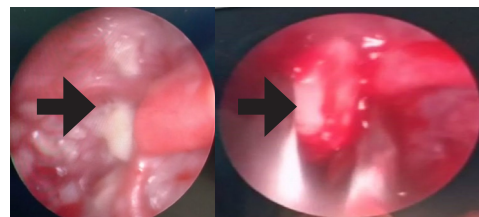
Picture 2. Panoramic radiograph



Picture 3. CT scan imaging of dentigerous cyst axial and coronal view



Picture 4. Dentigerous cyst with pus in dextra maxillary sinus. Cystic lesion was enucleated under general anesthesia with the Caldwell Luc procedure



Picture 5. Canine was seen in maxillary wall

pus or blood coming out of the nasal cavity, or open wound gingivobuccal sulcus.

## METHODS

Literature search was conducted on October 2nd, 2020, with keywords: “dentigerous maxillary cyst”, “Odontogenic sinusitis”, AND “Caldwell Luc”. Results of research are on PubMed, Wiley Online Library, Semantic Scholar, Dental Sciences, ResearchGate, and Hand searching is also done to search for evidences.

The literature search was performed using the following inclusion criteria: 1) dentigerous maxillary cyst patient. 2) ectopic maxillary teeth. 3) odontogenic sinusitis. 4) management of dentigerous maxillary cyst. The title and the definition of the procedure described is a modified transnasal endoscopic medial maxillectomy, and it is not suitable with Caldwell Luc procedure, thus the literature is excluded from the analysis.

## RESULT

Gendviliene et al.<sup>10</sup> said dentigerous cyst is generally treated mostly by total enucleation, marsupialization or decompression of cyst and removal with or without extraction of impacted teeth. The criteria for selecting treatment modalities depend on the size and location of the cyst, the age of the patient, teeth and involvement of vital structures. Marsupialization is performed in large cyst.

Kasat et al.<sup>7</sup> said that the treatment of choice for dentigerous maxillary cyst is the enucleation and extraction of the tooth associated with Caldwell Luc approach consisting of a sublabial incision followed by osteotomy of the anterior maxillary sinus wall and antrostomy of the inferior meatus. The Caldwell Luc procedure is the classic choice in the management of dentigerous maxillary cyst with high success rate.

Patel et al.<sup>11</sup> said that infected dentigerous cyst with acute symptoms requires antibiotic treatment with amoxicillin-clavulanic acid or clindamycin. Other useful antibiotics are trimethoprim-sulfamethoxazole or doxycycline, cefuroxime, ceftriaxone, cephalexin, ceftiofloxacin, and azithromycin. Odontogenic sinusitis

may develop and cause serious complications such as cerebral abscess.

The decision to choose what type of procedure for certain cases is depend on the size, location of the cyst, the age of the patient, ectopic teeth and less risk of post-operative complication. The Caldwell Luc procedure accompanied by tooth extraction and systemic antibiotic (ceftriaxone-clindamycin) gives good results without complication.

## DISCUSSION

About 70% of dentigerous cyst is found in the mandible, while 30% are found in the maxilla. Most often, the dentigerous cyst is associated with the lower third molar followed by the maxillary canine. However, dentigerous cyst that is associated with ectopic teeth in the maxillary sinus is very rare and only a few cases have been reported in literatures.<sup>5</sup> Research conducted by Lindahl et al. in 1981, in 29 samples had found canine (2), first premolar (5), second premolar (11), first molar (17), second molar (10) in the sample as the cause of rhinosinusitis. While the research by Melen et al. in 1986, in 99 samples had found a second incisor (1), canine (4), first premolar (11), second premolar (23), first molar (56), second molar (34), third molar (9) in the sample caused rhinosinusitis.<sup>12</sup> In this case, an infected dentigerous cyst was found in the dextra maxillary sinus caused by an ectopic dexra superior canine.

Dentigerous cyst is often noted as incidental findings on radiography because most of these cysts do not show any symptoms, unless they become secondary to infection. Dentigerous cyst can develop and cause facial asymmetry. Like other cysts, the dentigerous cyst extends the cortical plate and may involve other teeth which may cause tissue damage when developing.<sup>13,14</sup> Symptoms appeared on this patient matched the literature, with the finding of asymmetry on the right side of the face because of the right cheek lump is pressing into the right side of the nose with thinning of the cortex of the maxillary maxilla.

The infected dentigerous cyst can cause odontogenic sinusitis. Odontogenic sinusitis is a

unilateral infection of the maxillary sinus caused by dental infection. Odontogenic sinusitis can be found in aerobic and anaerobic oropharyngeal flora such as *Streptococcus*, *Bacteroides*, *Veillonella*, *Fusobacterium* and others. Periapical infections can sometimes reach the maxillary sinus which causes odontogenic sinusitis due to the proximity of the superior-posterior teeth. Other causes of odontogenic sinusitis include periodontitis, perforation of sinus *Schneider* membrane during extraction or surgery, or the presence of root tip or other foreign object such as endodontic obturation material in the sinuses. Palatal root from the first molar is the part most often associated with odontogenic sinusitis.<sup>15</sup> Clinical symptom include purulent rhinorrhea from dextra nasal cavity because of the finding of pus in the dextra maxillary sinus in durante surgery. This finding corroborates in panoramic radiograph that showed a firm boundary zone with a base on the root and visible dental component in it and appeared to urge the teeth on the right side of the maxilla and concluded the dentigerous cyst, DD/radicular cyst, showed odontogenic sinusitis in patient. Ectopic teeth in the maxillary sinus can cause sinusitis and throbbing cyst, keratocystic odontogenic tumor, odontoma and hardened fibrous bone tumor. There is an evidence that odontogenic maxillary sinusitis represents 10% of all maxillary sinusitis. According to Maillet, the incidence can increase to 51.8%. In terms of clinical symptoms, many patients with odontogenic sinusitis do not refer to upper tooth pain. The most common symptoms are nasal obstruction, facial pain, headache, snoring, acute sinus perforation and swelling. Odontogenic sinusitis can also manifest in the form of nasal congestion or discharge, facial pressure, anosmia and cacosmia. The patient may have a dental infection or have had oral surgery previously. Diagnosis was based on a combination of clinical symptoms and radiographic findings. When sinusitis is unilateral and unresponsive to treatment, odontogenic sinusitis must be considered.<sup>15</sup> In this case, the patient shows symptoms in the form of facial lump that pushes into the right side of the nose so that it looks asymmetrical since 5 months and is painless, right nasal obstruction, yellowish discharge, sometimes accompanied by a

headache on the right side that occurs slowly. This is due to the involvement of the right maxillary sinus and the cyst that fills the maxillary sinus which pushes the medial wall of the maxillary sinus into the right nasal cavity. History of taking amoxicillin-clavulanate for 2 weeks, but complaints did not reduce. Therefore, the suspicion of a dentigerous cyst with odontic sinusitis is considered.

Radiograph showed unilocular lesion, radiolucent which were clearly marked sclerotic edges and associated with crowns of unerupted teeth.<sup>2,3</sup> Teeth or root tooth may be present in the sinus cavity. Such teeth may be associated with nearby dentigerous cyst. Ectopically, the eruption associated with dentigerous cyst in the maxillary sinus is apparently can cause maxillary sinusitis.<sup>13,14</sup> Conformity based on panoramic radiographic findings in this patient showed the presence of unilocular lesion with the sclerotic edge and associated crowns of unerupted teeth in the dextra maxillary sinus. Panoramic radiograph have weaknesses, namely anatomical superimposition, and visualizing the topographic relationship between the upper molar and maxillary sinus may be difficult. However, ectopic molar in the maxillary sinus can be easily diagnosed with panoramic radiograph. Water's imaging provides good visualization of sinuses, but it is useless to detect ectopic molar in the maxillary sinus. The three-dimensional imaging system displays several parts of the maxillary sinus (bone and soft tissue), while Computed Tomography (CT) removes structural superimposition.<sup>15</sup> Based on CT imaging of the paranasal sinuses without contrasting visible hypodense lesion, firm boundary size is around 3.45x3.45x4.14 cm in right to middle maxilla and right maxillary sinus with bowing and thinning of the maxillary os cortex, visible tooth structure in the lesion. There is no visible connection or thickening of the mucosa in the ethmoidal, frontal, and sphenoidal sinuses. CT imaging of the paranasal sinuses by contrast with the impression of the right maxillary dentigerous cyst.

*Cone-Beam Computed Tomographic* (CBCT) imaging is a more effective imaging system, showing apical periodontitis and mucosal thickening, and

dental pathology associated with the maxillary sinus. CBCT scanning is a three-dimensional radiography that produces high-resolution images with low-dose radiation, compared to conventional computer tomography scanning. CBCT is a further modality for diagnosing large, sagittal, coronal, and axial cyst to eliminate superimposition of anatomic structures. Differential diagnosis of dentigerous cyst includes ameloblastoma, adenomatoid odontogenic tumor, ameloblastic fibroma, periodontal cyst, and odontogenic tumor of keratocyst.<sup>10</sup> CBCT was not performed on this patient because with correct historical findings, appropriate clinical examination, and panoramic radiograph and CT imaging of the paranasal sinuses, had directed the working diagnosis of dentigerous cyst with secondary infection in the form of dexra odontogenic sinusitis.

Histopathologically, the dentigerous cyst is a stratified epithelial non-keratinized epithelium consisting of mucocebaseus, ciliated, and rarely sebaceous cells.<sup>10</sup> Early diagnosis and treatment of odontogenic cyst lesion is very important to prevent morbidity. Imaging studies include the assistance of CT imaging in the diagnosis of dentigerous cyst and related dental abnormalities. Knowledge of histopathological features helps ensure the diagnosis. Management of a dentigerous cyst arising from an ectopic third molar in the maxillary sinus is usually enucleation. If left untreated, it has a tendency to turn into a tumor.<sup>14</sup> Dentigerous cyst is generally treated mostly by total enucleation, marsupialization or decompression of cyst and removal with or without extraction of impacted teeth. The criteria for selecting treatment modalities depend on the size and location of the cyst, the age of the patient, teeth and involvement of vital structures.<sup>10</sup> The treatment of choice for dentigerous maxillary cyst is the enucleation and extraction of the tooth associated with Caldwell Luc approach consisting of a sublabial incision followed by osteotomy of the anterior maxillary sinus wall and antrostomy of the inferior meatus.<sup>7</sup> Marsupialization is performed in large cyst. In dentigerous maxillary cyst, the endoscopic approach is one of the options in the management of dentigerous maxillary cyst.<sup>9</sup>

The Caldwell Luc procedure is the classic choice in the management of dentigerous maxillary cyst with high success rate.<sup>7</sup> In this case, dentigerous maxillary cyst extirpation was performed using the Caldwell Luc procedure accompanied by tooth extraction in the right maxillary sinus because ectopic teeth (canine) might cause recurrent odontogenic sinusitis and purulent rhinorrhea even with repeated antibiotic.

Infected dentigerous cyst with acute symptoms requires antibiotic treatment with amoxicillin-clavulanic acid or clindamycin. Other useful antibiotics are trimethoprim-sulfamethoxazole or doxycycline, cefuroxime, ceftriaxone, cephalexin, cefoxitin, and azithromycin. Odontogenic sinusitis may develop and cause serious complications such as cerebral abscess. Akhaddar reports orbital abscesses associated with odontogenic sinusitis.<sup>11</sup> The administration of ceftriaxone in this patient is in accordance to the sensitivity of the germs that cause odontogenic sinusitis by dentigerous cyst with secondary infection during hospitalization.

Dentigerous cyst can cause complications such as pathological bone fractures, permanent tooth loss, bone deformation, and malignancy. Complications from Caldwell Luc procedure includes damage to the tooth root, damage to the orbital floor, hypesthesia or cheek paresthesia due to infraorbital nerve injury, infection, bleeding and oroantral fistula.<sup>16</sup> On the first day after the surgery there was no diplopia, hypesthesia or right cheek paresthesia, infection, bleeding and oroantral fistula, thus outpatient is allowed and the patient is advised to take oral clindamycin 150 mg q.i.d for 5 days. Satisfactory results is achieved seven day after the surgery, there is no cheek hypoesthesia, lump on the right cheek, symmetrical face, rhinorrhea, pus or blood coming out of the nasal cavity, or gingivobuccal sulcus wound. The patient is advised to go to dentist regularly.

Appropriate early diagnosis and thickening of the dentigerous cyst lesion is very important to prevent secondary infections and morbidity. Detection of clinical symptoms, physical examination and investigation in the form of panoramic radiograph and CT imaging to assess abnormalities that appear in the

maxillary sinus and its surroundings, and associated with abnormalities of the teeth. The administration of systemic antibiotic and the Caldwell-Luc procedure accompanied by tooth extraction and primary closure provide satisfactory results.

## REFERENCES

1. Sharma S, Chauhan JS. Bilateral Ectopic Third Molars in Maxillary Sinus Associated with Dentigerous Cyst – A Rare Case Report. *International Journal of Surgery Case Reports*. 2019;61:298–301.
2. Veera SD, Padanad G. Dentigerous Cyst with Recurrent Maxillary Sinusitis; A Case Report with Literature Review. *IJADS*. 2015;1(4):16–19.
3. Smith RA. *Jaw Cyst*. In: *Current Diagnosis & Treatment*. Second Edition. New York: Mc Graw Hill; 2008.p.374–391.
4. Jendi SK, Shaikh S. The Tooth Crossing the Confinement of Mandible: An Unique Expression of Central Variety of Dentigerous Cyst. *Indian J Otolaryngol Head & Neck Surgery*. 2019.
5. Andrade NA, Choradia SS, Sahu VV, Aggarwal N. Dentigerous Cyst Presenting as Maxillary Sinusitis: A Rare Case Report. *IJSS*. 2016;2(9):16–18.
6. Jiang Q, Xu GZ, Yang C, Yu CQ, He DM, Zhang ZY. Dentigerous Cysts Associated with Impacted Supernumerary Teeth in the Anterior Maxilla. 2011;2(5):805–809.
7. Kasat OV, Karjodkar FR, Laddha RS. Dentigerous Cyst Associated with An Ectopic Third Molar in the Maxillary Sinus: A Case Report and Review of Literature. *Contemporary Clinical Dentistry*. 2012;3(3):373–6.
8. Alkhudair B, Alkhatib A, Alazzeah G, Almomen A. Bilateral Dentigerous Cysts and Ectopic Teeth in Maxillary Sinuses: A Case Report and Literature Review. *International Journal of Surgery Case Reports*. 2019;55:117–20.
9. Wardani RS, Lekatompessy M, Senior BA. Modified Transnasal Endoscopic Medial Maxillectomy with Inferior Turbinate Flap for Dentigerous Cyst. *Oto Rhino Laryngologica Indonesiana*. 2015;25(2):151–159.
10. Gendviliene I, Iegrand P, Nicolielo LFP, Sinha D, Spaey Y, Politis C, et al. Conservative Management of Large Mandibular Dentigerous Cysts with A Novel Approach for Follow Up: Two Case Reports. *Basic Dental and Maxillofacial Journal*. 2017;19(1):24–32.
11. Patel PV, Kumar S, Amrita P. Periodontal Abscess: A Review. *Journal of Clinical and Diagnostic Research*. 2011;5(2):404–409.
12. Lechien JR, Filleul O, Araujo PCD, Hsieh JW, Chantrain G, Saussez S. Chronic Maxillary Rhinosinusitis of Denal Origin: A Systematic Review of 674 Patient Cases. *Int J Otolaryngol*. 2014;9.
13. Girish G, Kumar M, Umashankar, Sharma R, Veeresh M, Bhandari A. Case Report Dentigerous Cyst in Maxillary Sinus: A Rare Occurrence. *International Journal of Oral and Maxillofacial Pathology*. 2011;2.
14. Guruprasad Y, Chauhan D S, Kura U. Infected Dentigerous Cyst of Maxillary Sinus Arising from an Ectopic Third Molar. *J Clin imaging Sci*. 2013;3(1):7.
15. Lopez-Carriches C, Lopez-Carriches I, Bryan R B. Odontogenic Sinusitis Caused by An Inflammation of A Dentigerous Cyst and Subsequent Finding of A Fibrous Dysplasia. A Case Report. *Open Dent J*. 2016;10:647–655.
16. Baranwal HC, Verma PK, Dwivedi CD, Srivastava R. Dentigerous Cyst Associated with An Impacted Maxillary Mesiodens. *European Journal of General Dentistry*. 2012;1(1):50–52.